



Synchronous Appendiceal Triple Primary Neoplasms and Acute Abdomen—A Case Report

Yung Sung Yeh¹, Chieh-Fan Chen^{2,3,*}, Pin-Chun Lin⁴, Chin-Liang Lin⁵, Te-Fu Huang², Chin-Ming Su⁶

¹Division of Trauma and Surgical Critical Care, Department of Surgery, Kaohsiung Medical University Hospital, Kaohsiung Medical University, Kaohsiung, Taiwan

²Department of Emergency, Kaohsiung Municipal United Hospital, Kaohsiung, Taiwan

³Faculty of Medicine, Kaohsiung Medical University, Kaohsiung Medical University, Kaohsiung, Taiwan

⁴Department of Pathology, Kaohsiung Municipal United Hospital, Kaohsiung, Taiwan

⁵Department of Surgery, Kaohsiung Municipal United Hospital, Kaohsiung, Taiwan

⁶Department of Urology, Kaohsiung Municipal United Hospital, Kaohsiung, Taiwan

Abdominal pain is a very common presenting symptom in the emergency department (ED). To reach an accurate diagnosis one must consider the possibility of multiple conditions that might cause the presenting symptom. We reported a female patient who came to our ED due to aggravated right lower quadrant abdominal pain for several hours. Multiple diagnosis of right T11 herpes zoster, right urolithiasis with hydronephrosis, appendiceal collision tumors of adenocarcinoma arising from adenoma and neuroendocrine tumor as well as leiomyoma in the surrounding adipose tissue were made. Histological examination and immunohistochemistry support these three lesions as separate entities. This case is unique because her multiple combined illness present as abdominal pain. Each one could be the cause of chief complaint, across dermatologic, urologic and neoplastic disorders.

Key words: *abdominal pain, appendiceal collision tumor, synchronous/multiple primary neoplasms*

Introduction

Abdominal pain is a common complain at emergency department (ED).¹ We report a 66-year-old Asian female presented at ED due to acute abdominal pain and her final diagnosis are synchronous triple primary neoplasms, right urolithiasis with hydronephrosis, as well as right T11 herpes zoster. Her synchronous triple primary neoplasms are collision tumors of neuroendocrine tumor and adenocarcinoma arising from sessile serrated adenoma in the appendix as well as leiomyoma in the peri-appendiceal adipose tissue. To the best of our knowledge, this particular combination condition on an abdominal pain patient had never been reported.

Case Report

A 66-year-old female suffered from persistent right lower quadrant (RLQ) abdominal pain for a few days. But aggravated intensity bothered her since several hours before ED visit. Her temperature was 36.1°C, pulse rate 70 beats/min, blood pressure of 136/75 mmHg and respiratory rate 19 breaths/min. Vesicles on the reddish base skin at right T11 dermatome was found, and local tenderness at RLQ region with right frank knocking pain were the co-exist presentations.

Laboratory tests showed a white cell count of 12,960/ μ L with neutrophilia (92.2%). Chemistry survey were within normal limits. Urinary analysis

Received: November 25, 2017; Revised: March 22, 2018 (2nd); Accepted: March 27, 2018.

*Corresponding author: Chieh-Fan Chen, MD, MS, Department of Emergency, Kaohsiung Municipal United Hospital, No. 976, Zhonghua 1st Rd., Gushan Dist., Kaohsiung 804, Taiwan; Faculty of Medicine, Kaohsiung Medical University, No. 100, Tzyou 1st Rd., Sanmin Dist., Kaohsiung 807, Taiwan. E-mail: ccf97704515@gmail.com

revealed pyuria as white blood cell (WBC) = 10–19/high-power field (HPF), microscopic hematuria as 3–5/HPF. Computed tomography (CT) showed right upper third ureteral stone with right hydronephrosis and hydroureter, swelling and hyperemic change of appendix, favor acute appendicitis or other entity (Fig. 1).

The intraoperative findings revealed a retrocecal enlarged grayish-white color appendix with diffuse firm contents without perforation, redness, maceration, nodulation. Adhesion of jejunum and cecum was found. There was no palpable lymphadenopathies (LAPs), exudates, neither ascites. Initial appendectomy was performed.

Histologically, the appendectomy specimen shows three different types of tumors. Neuroendocrine tumor, grade 1, is identified at the tip of appendix. The neoplastic cells are bland-looking with arrangement of trabecular and cord pattern. Invasion into submucosa is present. They are positive for synaptophysin, cluster of differentiation 56 (CD56), and chromogranin A immunostains (Fig. 2). The whole mucosa of appendix shows diffuse sessile serrated adenoma, with different degree of dysplasia. In area of high grade dysplasia, a few foci show neoplastic gland invades into submucosa with desmoplastic stromal reaction. The diagnosis of adenocarcinoma arising from sessile serrated adenoma was made. One leiomyoma was identified incidentally in periappendiceal adipose tissue. It was composed by bland-looking spindle cells proliferation and they were positive for smooth muscle actin (Fig. 3).

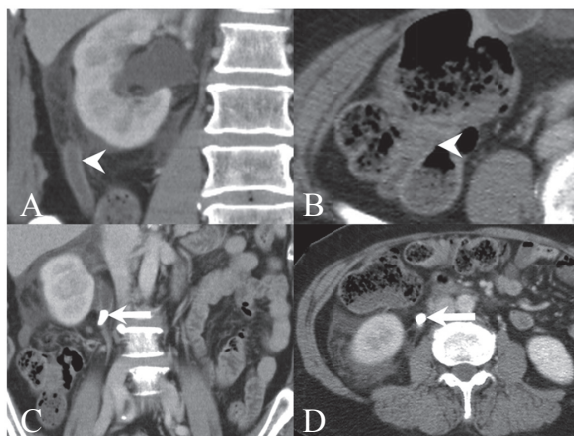


Fig. 1. A swelling and hyperemic appendix towards up at retrocecal location (A). Original junction of appendix from cecum (B). Right upper third ureteral stone (arrow) with hydronephrosis and hydroureter in coronal view (C) and axial view (D).

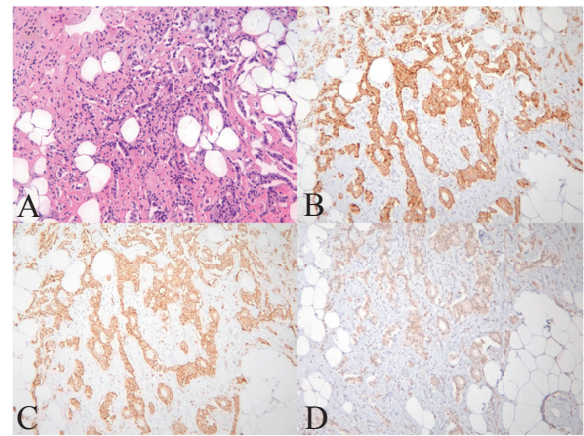


Fig. 2. Neuroendocrine tumor, grade 1 (A). Tumor cells are strongly positive for synaptophysin (B), cluster of differentiation 56 (CD56) (C), and weakly positive for chromogranin A (D).

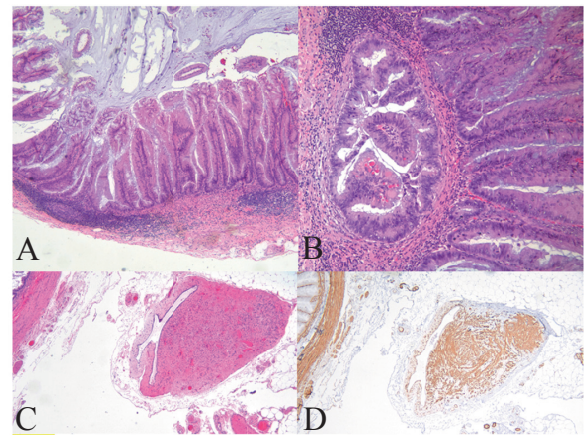


Fig. 3. The whole mucosa of appendix shows diffuse sessile serrated adenoma, with different degree of dysplasia (A). The neoplastic gland invades into submucosa with desmoplastic stromal reaction, adenocarcinoma (B). A leiomyoma is present in periappendiceal soft tissue (C). It shows diffuse positive staining of smooth muscle actin (D).

There was no further intra-abdominal discomfort found during her stay in the hospital. She had an uneventful recovery course and was discharged on the 6th day after hospitalization. Currently, this patient received regular follow-up at our surgical outpatient department.

Discussion

Dermatome distributing skin rash with preexisting pain suggest us herpetic zoster. However, aggra-

vated intensity of symptom and physical findings alert another co-existed problem. Local tenderness at RLQ region with right frank knocking pain requires further evaluations. Equivocal urinary analysis didn't stop our investigation. CT findings imply right urolithiasis and appendiceal disorder. Old age and negative-fever history and other findings hint possible risk of neoplasm prior to surgical intervention.

This female patient was found to have collision tumor in her appendix. Collision tumor means two histologically different neoplasias that grow at the same anatomic location without transition and with a different clonal origin.² According to the updated World Health Organization (WHO) Classification of Tumours of the Digestive System, Fourth Edition,³ this female had separated adenocarcinoma arising from sessile serrated adenoma and neuroendocrine tumor. It is not compatible with so-called mixed adeno-neuroendocrine carcinoma (MANEC) because they do not intermix with each other. By the way, she also had a leiomyoma in the surrounding adipose tissue. This is the second reported synchronous triple neoplasms of appendix after Meeks et al.⁴ Besides the triple appendix tumors, Meeks et al. also found the nearby fourth colon adenocarcinoma.⁴

There were several type of appendiceal collision tumors of the appendix. They were reported as mucinous neoplasm and carcinoid,^{2,5,6} as well as adenocarcinoma and small cell carcinoma.^{7,8} Some reports presented as collision tumors in the appendix but may be not.⁹ Our report is the only case of collision tumor formed by a well differentiated neuroendocrine tumor and an early stage adenocarcinoma.

There was no evidence of metastasis at peritoneum, liver or lung. With regard to her adenocarcinoma, T1 was staged as sessile serrated adenoma with low grade dysplasia at the margin, which was in the junction of appendix and colon. Even though re-exploration with right hemicolectomy was suggest during hospitalization,¹⁰ the family refused. This patient's neuroendocrine tumor was located at the tip of the appendix, just as most common location as reported. It was staged grade 1 with negative margins. Appendectomy was considered curative and no further staging or postoperative surveillance was carried out.¹¹

Classification of Tumours of the Digestive System has been updated in 2010³ but misused term still occurred. We presented this rare case to remind readers that the obvious finding may not be the major problem and the cause of chief complaint may not be

just due to one medical condition. Keep an open mind to all possible differential diagnosis in the ED could provide early and accurate management of patients.

Conclusion

Coexisting right T11 herpes zoster, right urolithiasis with hydronephrosis, appendiceal collision tumors of adenocarcinoma with neuroendocrine tumor as well as periappendiceal leiomyoma present as acute abdominal pain is extremely rare. We should always keep all possible differential diagnosis in mind. With thorough history taking, physical examination and appropriate workup, the patient will receive the best management, even in the rare cases.

Conflicts of Interest Statement

No conflicts of interest support. All authors declare that they have no financial conflicts.

Acknowledgment

Ethical Approval

We did not seek Institutional Review Board (IRB) approval for this case report, which contains only retrospective, de-identified patient information. The writing or publication of this case report did not affect this patient's treatment or outcomes in any way. There are no ethical dilemmas with this case.

Author Contributions

Shu-Lin Chen: primary author, researcher, Head Nurse of Emergency Department. Chieh-Fan Chen: corresponded author, researcher, physician of Emergency Department. Pin-Chun Lin: pathologist, provided pictures and captions. Chin-Liang Lin: attending Surgeon of patient. Te-Fu Huang: physician of emergency department. Chin-Ming Su: consultant urologist.

References

1. Thijssen WA, van Mierlo E, Willekens M, et al. Complaints and diagnoses of emergency department patients in the Netherlands: a comparative study of integrated primary and emergency care. *PLoS One* 2015;10:e0129739. doi:10.1371/journal.pone.0129739
2. Baena-del-Valle J, Palau-Lázaro M, Mejía-Arango M, et al. Well differentiated neuroendocrine tumor of the ap-

- pendix and low-grade appendiceal mucinous neoplasm presenting as a collision tumor. *Rev Esp Enferm Dig* 2015;107:396-398.
3. Bosman FT, Carneiro F, Hruban RH, Theise ND. *WHO Classification of Tumours of the Digestive System*. 4th ed. Lyon, France: International Agency for Research on Cancer; 2010.
 4. Meeks MW, Grace S, Chen Y, et al. Synchronous quadruple primary neoplasms: colon adenocarcinoma, collision tumor of neuroendocrine tumor and schwann cell hamartoma and sessile serrated adenoma of the appendix. *Anticancer Res* 2016;36:4307-4311.
 5. Tan HL, Tan GH, Teo M. Two rare cases of appendiceal collision tumours involving an appendiceal mucinous neoplasm and carcinoid. *BMJ Case Rep* 2016;2016:bcr2015213938. doi:10.1136/bcr-2015-213938
 6. Dellaportas D, Vlahos N, Polymeneas G, et al. Collision tumor of the appendix: mucinous cystadenoma and carcinoid. A case report. *Chirurgia (Bucur)* 2014;109:843-845.
 7. Rossi G, Bertolini F, Sartori G, et al. Primary mixed adenocarcinoma and small cell carcinoma of the appendix: a clinicopathologic, immunohistochemical, and molecular study of a hitherto unreported tumor. *Am J Surg Pathol* 2004;28:1233-1239. doi:10.1097/01.pas.0000128666.89191.48
 8. Chetty R, Klimstra DS, Henson DE, Albores-Saavedra J. Combined classical carcinoid and goblet cell carcinoid tumor: a new morphologic variant of carcinoid tumor of the appendix. *Am J Surg Pathol* 2010;34:1163-1167. doi:10.1097/PAS.0b013e3181e52916
 9. Singh NG, Mannan AASR, Kahvic M, Nur AM. Mixed adenocarcinoma-carcinoid (collision tumor) of the appendix. *Med Princ Pract* 2011;20:384-386. doi:10.1159/000324870
 10. Kelly KJ. Management of appendix cancer. *Clin Colon Rectal Surg* 2015;28:247-255. doi:10.1055/s-0035-1564433
 11. Ramage JK, Ahmed A, Ardill J, et al. Guidelines for the management of gastroenteropancreatic neuroendocrine (including carcinoid) tumours (NETs). *Gut* 2012;61:6-32. doi:10.1136/gutjnl-2011-300831