



Acute Pancreatitis Due to a Mushroom Impacted in a Juxtapapillary Duodenal Diverticulum

Chien-Wei Lai¹, Tsung-Hsing Lin¹, Choon-Hoon Hii¹, Chi-Wen Juan^{1,2,*}

¹Department of Emergency Medicine, Kuang Tien General Hospital, Taichung, Taiwan

²Department of Nursing, Hungkuang University, Taichung, Taiwan

Case Presentation

This 85-year-old woman, a patient of hypertension and diabetes, presented to the emergency department with epigastric discomfort and vomiting for one day. No peritonitis sign was found on arrival. Laboratory results were significant for lipase (4,179 U/L), aspartate transaminase/alanine transaminase (AST/ALT = 93/39 IU/L), glucose (315 mg/dL), but normal triglyceride and calcium levels. Acute pancreatitis was diagnosed. Abdominal computed tomography (CT) scanning revealed a huge juxtapapillary diverticulum causing common bile duct dilatation (Fig. 1). An intact mushroom in the diverticulum was later identified (Fig. 2) and removed endoscopically. She had an uneventful recovery.

Discussion

Duodenal diverticulum is an outpouching of the duodenal wall; it represents herniation of mucosa and submucosa through a muscular defect. Duodenal diverticula rank second behind the colon as the most common site of diverticulosis in the alimentary tract. More than 70% of duodenal diverticula are located close to the papilla Vater. Juxtapapillary or periampullary duodenal diverticula is interchangeably used to describe the close anatomic location.¹

Complications of duodenal diverticula can happen as inflammation, hemorrhage, obstruction, or perforation, like diverticula at other sites of the gastrointestinal tract. Inflammation and obstruction can

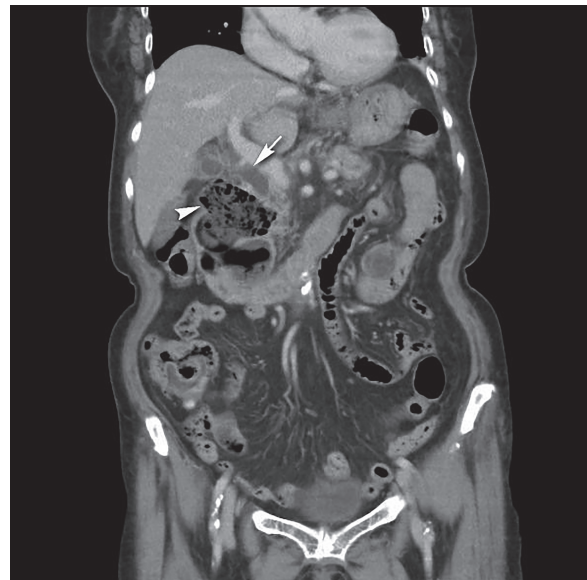


Fig. 1. Abdominal computed tomography (CT) showed a huge juxtapapillary diverticulum (arrowhead) and dilatation of the common bile duct (arrow).

overlap in large Juxtapapillary duodenal diverticula because of the close anatomic location to the ampulla. Cases of Juxtapapillary duodenal diverticular bezoar are rare; however, it may present as acute pancreatitis or biliary obstruction.^{2,3} Bezoars are concretions of indigestible materials in the gastrointestinal tract. It can be non-food materials or indigested foods generally in patients with previous gastric surgery or delayed gastric emptying. Most bezoars are encountered in

Received: November 15, 2017; Revised: February 2, 2018 (3rd); Accepted: February 9, 2018.

*Corresponding author: Chi-Wen Juan, Department of Emergency Medicine, Kuang Tien General Hospital, No. 117, Shatian Rd., Shalu Dist., Taichung 433, Taiwan. E-mail: juanchiwen@yahoo.com.tw

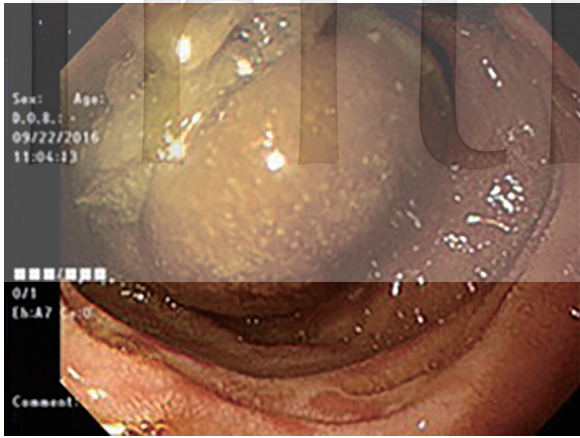


Fig. 2. An intact mushroom (5 × 5 cm) in the diverticulum was identified and removed endoscopically.

the stomach, but may be found in other location of the gastrointestinal tract. The case we presented was a patient presented as acute pancreatitis. Imaging studies revealed a periampullary lesion and obstructed pancreatobiliary tract. An undigested mushroom was later identified and removed from the Juxtapapillary duodenal diverticulum. No biliary stone or other obstructive lesion was found. She recovered uneventfully after endoscopic therapy.

In patients presenting with upper abdominal pain

or jaundice, pancreatobiliary obstruction can easily be identified with ultrasonography and CT scanning. Most of the obstruction is attributed to biliary stones or periampullary tumors; however, large periampullary duodenal diverticula can bring a similar picture. Although surgery can be inevitable in some cases of complicated duodenal diverticula with bezoars, endoscopy with or without retrograde cholangiopancreatography is helpful not only in diagnosis but also in treatment.

References

1. Schroeder TC, Hartman M, Heller M, Klepchick P, Ilkhanipour K. Duodenal diverticula: potential complications and common imaging pitfalls. *Clin Radiol* 2014;69:1072-1076. doi:10.1016/j.crad.2014.05.103
2. van der Linde K, van der Linden GH, Beukers R, Cleophas TA. Food impaction in a duodenal diverticulum as an unusual cause of biliary obstruction: case reports and review of the literature. *Eur J Gastroenterol Hepatol* 1997;9:635-639. doi:10.1097/00042737-199706000-00021
3. Kim JH, Chang JH, Nam SM, et al. Duodenal obstruction following acute pancreatitis caused by a large duodenal diverticular bezoar. *World J Gastroenterol* 2012;18:5485-5488. doi:10.3748/wjg.v18.i38.5485